

Valve sparing surgery in an adult patient with dextrocardia and annuloaortic ectasia

Rahmi Zeybek¹, Ahmet Bacaksiz², Rasul Sharifov³, Emrah Sevgili², Yasin Ay¹

¹Department of Cardiovascular Surgery, Faculty of Medicine, BezmiÂlem Foundation University, Istanbul, Turkey

²Department of Cardiology, Faculty of Medicine, BezmiÂlem Foundation University, Istanbul, Turkey

³Department of Radiology, Faculty of Medicine, BezmiÂlem Foundation University, Istanbul, Turkey



Kardiologia i Torakochirurgia Polska 2016; 13 (1): 42-44

Abstract

We report the case of a patient with situs inversus totalis, annuloaortic ectasia complicated by aortic insufficiency and mitral regurgitation which induced congestive heart failure. Both valvular lesions were repaired physiologically using aortic root sparing Yacoub 'remodeling' technique and mitral ring annuloplasty. Valve sparing techniques can be used effectively even in patients with complicated clinical scenarios (like dextrocardia and annuloaortic ectasia) to avoid the potential risks related to prosthetic valve implantation and lifelong anticoagulation therapy.

Key words: situs inversus, dextrocardia, aortic aneurysm.

Streszczenie

W pracy przedstawiono przypadek pacjenta z całkowitym przełożeniem trzewi (*situs inversus totalis*) i ektazją pierścieniowo-aortalną powikłaną przez niedomykalność zastawki aortalnej i mitralnej, czego rezultatem była zastoinowa niewydolność serca. Obie zmiany zastawkowe naprawiono fizjologicznie przy zastosowaniu oszczędzającej pień aorty techniki Yacouba i plastyki pierścienia mitralnego. Techniki oszczędzających zastawkę można używać skutecznie nawet u pacjentów o skomplikowanym obrazie klinicznym (np. w przypadku dekstrakardii i ektazji pierścieniowo-aortalnej), aby uniknąć potencjalnych zagrożeń związanych z implantacją sztucznej zastawki i dożywotnim stosowaniem terapii przeciwkrzepliwej. **Słowa kluczowe:** przełożenie trzewi, dekstrocardia, tętniak aorty.

Introduction

Dextrocardia as a component of situs inversus totalis and annuloaortic ectasia complicated by multivalvular insufficiency is a very rare clinical entity which was traditionally treated with a modified Bentall procedure and mitral valve replacement [1-3]. Here, we report the case of a patient with dextrocardia, annuloaortic ectasia, mitral and aortic regurgitation, who presented with congestive heart failure and underwent surgery involving the replacement of the ascending aorta and ring annuloplasty for both valves.

Case study

The 42-year-old male patient was admitted to the hospital with progressive dyspnea. The patient had been diagnosed with situs inversus totalis and dextrocardia and was asymptomatic until three months earlier. Physical examination revealed a right apical impulse with a II/VI holosystolic murmur at the 3rd right intercostal space and a grade III/VI diastolic murmur best heard at the left parasternal border.

Transthoracic echocardiography (TTE) demonstrated dextrocardia with impaired left ventricular ejection fraction (38%), severe aortic regurgitation associated with annuloaortic ectasia, as well as moderate mitral and tricuspid regurgitation. The patient underwent conventional diagnostic coronary angiography which revealed aneurysmal dilatation at both the left main and right coronary artery ostia and the right-sided aortic arch. The maximum diameter of the aortic annulus was 56 mm. Contrast-enhanced 64-slice multi-detector computed tomography demonstrated aneurysmal dilatation at the aortic annulus, the left main and right coronary arteries, right-sided aortic arch, absence of dilatation across the aorta, situs inversus totalis, and polysplenia (Fig. 1).

The surgery was performed using median sternotomy. When the pericardium was opened, dilatation of the aortic root and the roots of the right and left coronary arteries were observed. The locations of the innominate artery and both venae cavae on the left side were also detected.

Address for correspondence: Dr. Ahmet Bacaksiz, Department of Cardiology, Faculty of Medicine, BezmiÂlem Foundation University, Vatan Street, Fatih 34093 Istanbul, Turkey, phone: +90 533 204 17 16, fax: +90 (212) 621 75 80, e-mail: ahmetbacaxiz@gmail.com

Cardiopulmonary bypass was established using distal ascending aorta cannulation for arterial return, and bicaval cannulation for venous drainage. Myocardial protection was provided by antegrade and retrograde isothermic blood cardioplegia. After cross-clamping the aorta, left atriotomy was performed through the interatrial groove; there was a moderate dilatation at the mitral annulus, but the leaflets were normal (Carpentier type I). For this reason, a saddle-shaped ring (No. 30, Carpentier-Edwards Physio Annuloplasty Ring, Edwards Lifesciences, Irvine, CA, USA) was implanted and checked with the saline test, which revealed no regurgitation. Subsequently, the aorta was opened above the sinotubular junction and the morphology of the aortic sinuses and valve cusps was assessed. Annuloaortic ectasia involving the coronary ostia was observed, but leaflet anatomy was normal. The diseased ascending aorta and the dilated sinuses were excised, and only a 4-5 mm fragment of the aortic wall, attached to the annulus, was left behind. The coronary ostia were dissected without leaving the diseased segment for a button reimplantation during the root replacement procedure. For annular dilatation, subcommissural annuloplasty was performed at the three commissurae described by Cabrol *et al.* [4]. A 28-mm collagen-coated Dacron graft (Hemashield Microvel, Meadox Medicals Inc, Oakland, NJ, USA) was chosen and tailored for repair. The graft was incised vertically and scalloped in order to reproduce the crescentic shape of the annulus and to create pseudosinuses in the supravalvular region. The graft was sutured with three continuous 4/0 polypropylene sutures distributed symmetrically around the graft starting above each commissural pillar. Then, the coronary arteries were re-implanted. The graft was trimmed to length, and distal anastomosis was performed. The cardiopulmonary bypass was discontinued uneventfully. Control transesophageal echocardiography showed neither mitral nor aortic insufficiency. The postoperative course was uneventful. The patient was discharged on the 7th postoperative day and was prescribed a beta-blocker and acetylsalicylic acid. Six months after the surgery, a control CT scan revealed graft patency (Fig. 2).

Discussion

Dextrocardia with situs inversus totalis is a condition in which the heart and other visceral organs are situated on the right side instead of the left in a mirror-like fashion [1]. It is a very rare congenital anomaly affecting approximately 1-2 per 10,000 individuals in the general population [1-2]. Although the heart structure and life expectancy of most patients is normal, some congenital cardiac anomalies can be detected in 3-5% of the subjects. Adult patients with situs inversus are diagnosed incidentally during physical examination or radiological screening conducted for other reasons. The importance of diagnosing this anomaly in adulthood is to prevent errors in medical examinations, interventions, and surgical procedures. Surgery should be carried out from the left side in patients with dextrocardia, and RIMA should be generally selected as the conduit of choice to the LAD [3]. Moreover, in our case, the mitral repair was performed with

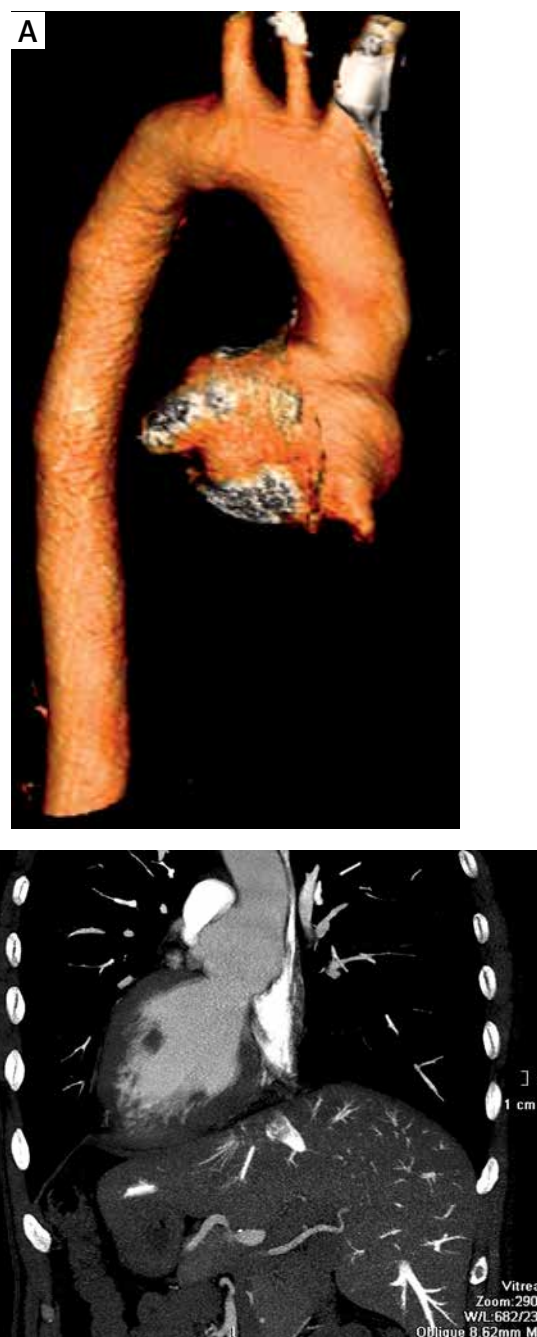

Fig. 1. Preoperative aortic annulus/root aneurysm associated with dilated left main coronary artery visualized by three-dimensional computed tomography (CT) using (A) a volume rendering technique and (B) multiplanar reformation CT, sagittal oblique view

the surgeon standing on the left side of the table. It was impossible to operate from the opposite side while performing a left atrial incision parallel to the interatrial groove, so the surgeon switched sides to facilitate surgery.

Surgical management of aortic insufficiency due to annuloaortic ectasia and mitral regurgitation resulting from left ventricular dilatation should also be discussed. Yokoyama *et al.* performed mitral valve replacement with a mechanical valve and a modified Bentall procedure with a composite valve graft in a similar case with dextrocar-

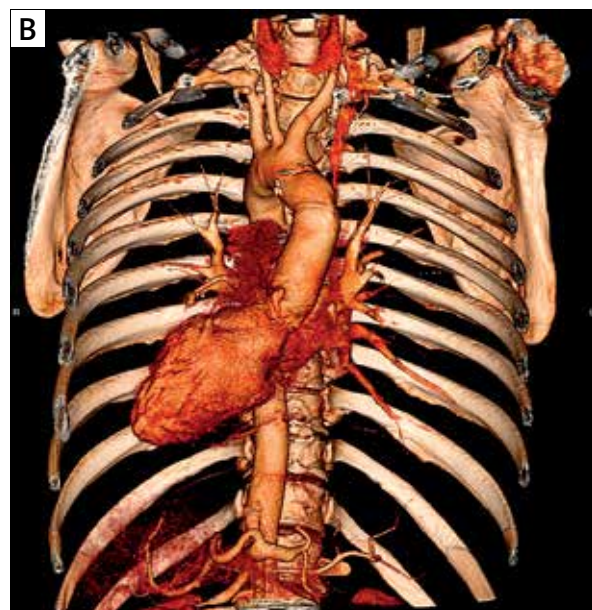
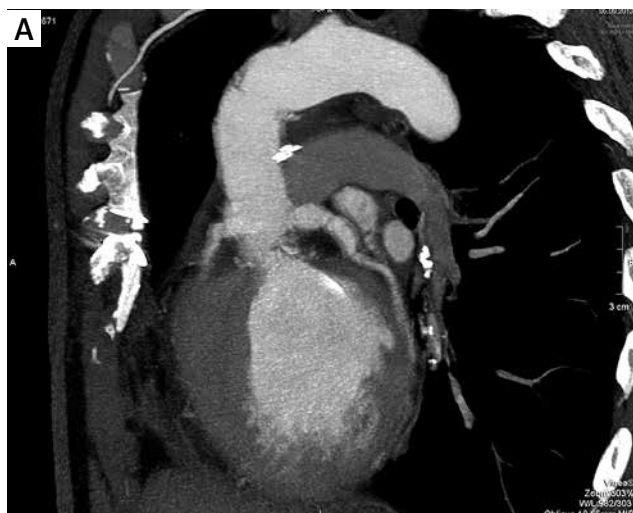

Fig. 2. Post-operative images of the aortic annulus/root using the same computed tomography (CT) techniques

dia and annuloaortic ectasia [3]. The disadvantages of this treatment include the need for lifelong anticoagulation therapy and potential risks related to prosthetic valves. Whether mitral valve repair or replacement in simultaneous mitral and aortic valve surgery would be associated with a better outcome remains uncertain; some investigators have recommended mitral valve reconstruction and aortic valve replacement as the preferred strategy whenever mitral valve repair is possible, while others have advocated double valve replacement as the standard procedure [4]. Complication rates did not differ between single valve replacement versus double valve replacement in patients with two valve pathologies. The ideal solution for such patients seems to be to repair both valves. In our case, the mitral regurgitation was Carpentier type I (presence of only annular dilatation, normal leaflets), and we performed annuloplasty with a saddle-shaped ring.

The aortic insufficiency in our patient resulted from annuloaortic ectasia and the leaflets were also normal. Aortic annuloplasty was performed by narrowing all three subcommissural triangles with 4/0 propylene pledgeted sutures (Cabrol technique). As an alternative to the Bentall procedure, Yacoub *et al.* and David *et al.* introduced two surgical techniques for valve-sparing aortic root replacement (VSARR). Tian *et al.* reviewed the literature to compare these two major valve-sparing operations: David's 'reimplantation' technique and the Yacoub's 'remodeling' technique [5]. The researchers concluded that moderate to severe aortic insufficiency was more common in the Yacoub procedure but the difference rarely reached statistical significance. In the David procedure, the basal ring, firmly anchored by the aortic graft, has the advantage of preventing further dilatation of the annulus. On the other hand, the biggest disadvantage of the reimplantation is the potential risk of impeding natural leaflet mobility in a rigid straight graft. The advantages of remodeling are that a bil-

lowed graft mimics the natural sinus of Valsalva and that the absence of subannular sutures preserves some distensibility within the complex, asymmetric deformation of the aortic root during the cardiac cycle.

Conclusions

Dextrocardia with situs inversus is a relatively rare congenital abnormality. In patients with this condition, annuloaortic ectasia and valvular insufficiencies can occur. Surgeons may need to switch their position during the operation. Techniques aiming to preserve normal physiology should be used when treating such patients, as is the case with patients with normal anatomy. With this in mind, we performed mitral ring annuloplasty for mitral regurgitation (Carpentier type I) and Cabrol subcommissural annuloplasty for aortic insufficiency in our patient. This is the first report in the literature that demonstrated the applicability of aortic valve sparing methods in such patients.

Disclosure

Authors report no conflict of interest.

References

1. Bohun CM, Potts JE, Casey BM, Sandor GG. A population-based study of cardiac malformations and outcomes associated with dextrocardia. *Am J Cardiol* 2007; 100: 305-309.
2. Garg N, Agarwal BL, Modi N, Radhakrishnan S, Sinha N. Dextrocardia: an analysis of cardiac structures in 125 patients. *Int J Cardiol* 2003; 88: 143-155.
3. Yokoyama Y, Satoh H, Abe M, Nagashima M, Kurata A, Higashino H. Cardiac surgery for annuloaortic ectasia and mitral regurgitation in an adult patient with dextrocardia. *Gen Thorac Cardiovasc Surg* 2011; 59: 341-343.
4. Kuwaki K, Kawaharada N, Morishita K, Koyanagi T, Osawa H, Maeda T, Higami T. Mitral valve repair versus replacement in simultaneous mitral and aortic valve surgery for rheumatic disease. *Ann Thorac Surg* 2007; 83: 558-563.
5. Tian D, Rahnavardi M, Yan TD. Aortic valve sparing operations in aortic root aneurysms: remodeling or reimplantation? *Ann Cardiothorac Surg* 2013; 2: 44-52.